

Contrary to some beliefs, the only way to accurately age a white-tailed deer is by examining their cheek teeth.

Nothing But the Tooth

Story By Kathy Andrews
Photos By Adele Hodde

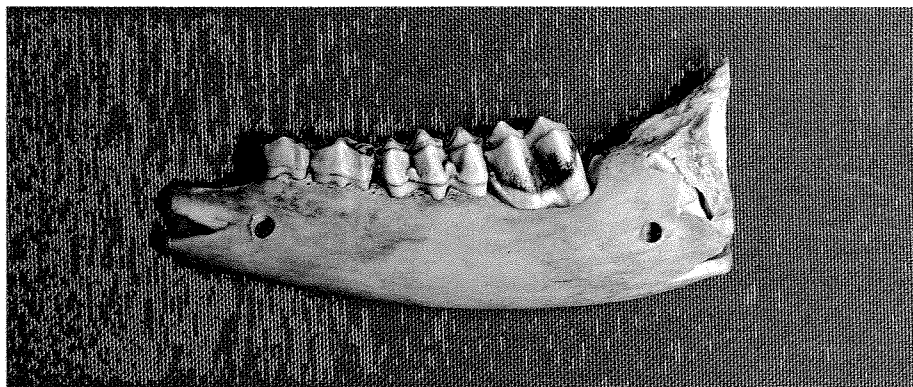
As a veteran deer check station operator, the most commonly asked question by hunters and the curious passers-by was: How old is my deer?

Over the years, people related their techniques for aging deer, everything from looking at a deer's incisors to counting the number of tines on a buck's rack or going on overall body size.

Starting this fall, deer check stations will continue only in a few counties to

allow for sampling for Chronic Wasting Disease. A new virtual deer check station, VCheck, will allow most hunters to quickly report harvested deer via computer or telephone.

But hunters may be left with a burning question: How old is my deer?



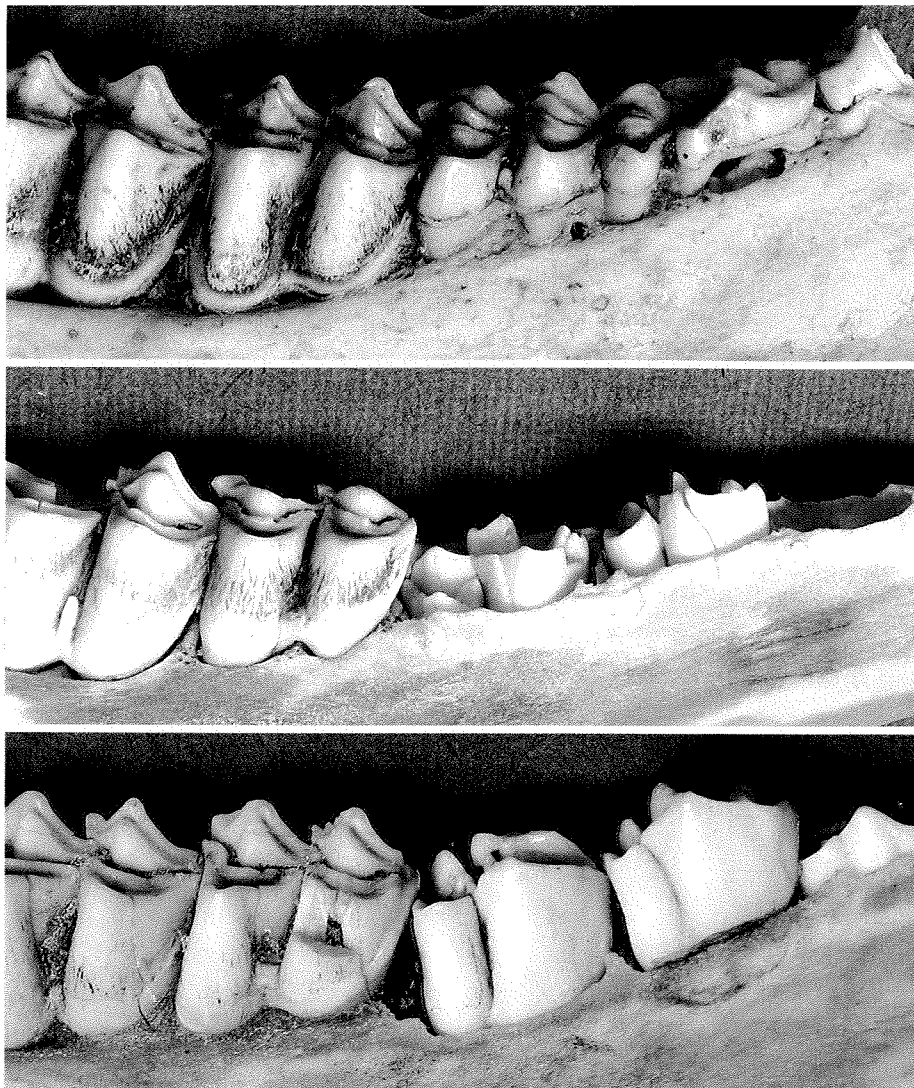
VCheck, Illinois' new virtual deer check station, will allow hunters to report their harvest from the comfort of their home. Here are some tips to help the curious sportsman learn to age a deer.

Here's how you can tell.

Science has proven that a quick, cheap and accurate way to age a deer is by examining tooth development and wear. Aging deer to age 3.5 years isn't difficult. Beyond that, it becomes more subjective.

"In Illinois, whitetails typically give birth in June, although some may be born as early as May or as late as September,"

Fawns typically have four or five cheek teeth.



(Photos by Joe McFarland.)

There is a lot of variation in the teeth of 1.5-year-old deer. The three pre-molars are replaced at this age, but some deer still have their original third premolar, identifiable by the three parts (cusps) that are greatly worn (top). The adult third premolar (having only two cusps) may be just beginning to erupt through the gum line of some deer (middle). In others, that tooth may have grown in, but will be cleaner and whiter than the adjacent molar (lower).

said Tom Micetich, Department of Natural Resources deer project manager. "That means that during the firearm season, all deer will be in years plus one-half—fawns will be 6 months old, last year's deer 1.5 years old and so forth."

To age a deer, look at the teeth found on one side of the lower jaw. At 6 months of age, whitetails have four or five cheek teeth, three pre-molars and one or two molars. At a year-and-a-half, the three pre-molars will be replaced with adult teeth and one or two additional molars will have erupted, for a total of

six cheek teeth. After this stage, aging is based on the amount of wear, with the white enamel layer decreasing and brown dentine layer increasing as teeth become worn.

Antler size and physical development cannot be used to determine age as there is considerable variation between deer. Genetics plays into both, but diet

VCheck

Deer hunters are going virtual and checking their deer at www.dnr.state.il.us/vcheck or by making a toll-free call to 1-866-452-4325 (1-866-ILCHECK).

As a part of the virtual check station process, hunters will submit information useful in monitoring the status of Illinois' deer herd. Among the questions asked are the number of antler points bucks possess that are in excess of 25 millimeters, circumference around the thickest antler, and on does, the distance in millimeters from the front tip of the right rear hoof to the rear of the base of the dew claw.

Additional information is available on the back of each deer permit.

Counties where mandatory manned check stations will continue, permitting sampling for Chronic Wasting Disease, are Stephenson, Winnebago, Boone, McHenry, Ogle, DeKalb and Kane.

has a big role. With a range of soil types and fertility from north to south and east to west, the nutritional value of the foods available to Illinois deer ranges widely, affecting antler growth and body size.

One word of advice from Micetich when aging your deer.

"In aging a recently harvested animal the teeth will not look as large as they are in photographs," Micetich explained. "Photographs are taken of clean jaws, making teeth seem larger than when the gum is present."



At 2.5 years of age six cheek teeth are present and negligible wear has occurred on the three molars. The third premolar is stained.

(Photo by Lori Jones.)

